Scientific Foundation SPIROSKI, Skopje, Republic of North Macedonia
South East European Journal of Immunology. 2023 Jun 06; 6(1):12-17.
https://doi.org/10.3889/seejim.2022.6030
eISSN: 1857-9388
Category: *Case Report*
Section: *Basic Immunology*

OPEN ACCESS

Advanced Platelet-rich Fibrin versus Sticky Bone in Socket Preservation - Clinical and X-ray Assessment: Case Report

Stavre Trajculeski[1]*, Daniela Veleska-Stevkovska[1], Marija Trajculeski[2]

[1]Department of Oral Surgery and Implantology, University Dental Clinical Center "St. Pantelejmon" - Skopje, Republic of North Macedonia; [2]Agency for Medicines and Medical Devices, Republic of North Macedonia

Edited by: Slavica Hristomanova-Mitkovska
Citation: Trajculeski S, Veleska-Stevkovska D, Trajculeski M. Advanced Platelet-rich Fibrin versus Sticky Bone in Socket Preservation - Clinical and X-ray Assessment: Case Report. South East Eur J Immunol. 2023 Jun 06; 6(1):12-17. https://doi.org/10.3889/seejim.2023.6030
Keywords: Advanced platelet-rich fibrin; Xenograft; Cone-beam computed tomography; Socket preservation; Bone regeneration
***Correspondence:** Stavre Trajculeski, Department of Oral Surgery and Implantology, University Dental Clinical Center "St. Pantelejmon" - Skopje, Republic of North Macedonia. E-mail: stavre_trajculeski@hotmail.com
Received: 20-Apr-2023
Revised: 05-May-2023
Accepted: 25-May-2023
Copyright: © 2023 Stavre Trajculeski, Daniela Veleska-Stevkovska, Marija Trajculeski
Funding: This research did not receive any financial support
Competing Interests: The authors have declared that no competing interests exist
Open Access: This is an open-access article distributed under the terms of the Creative Commons Attribution-NonCommercial 4.0 International License (CC BY-NC 4.0)

Abstract

BACKGROUND: The preservation of post-extraction alveola, as part of guided bone regeneration, is recommended for the creation of a biological foundation for future implant-prosthetic or prosthetic production. Several graft materials are used, either independently or in a combination of each other. Advanced platelet-rich fibrin (A-PRF) as an autologous blood derivate in the recent years has been increasingly used because of its properties in angiogenesis, epithelialization, and hemostasis. Simple production, low cost, and non-use of anticoagulants are advantages for more mass use of it.

CASE PRESENTATION: Two clinical cases are described, one is using a combination of A-PRF with xenograft, and the second clinical case is using a solo A-PRF, for socket preservation.

CONCLUSION: The properties of A-PRF for preserving both bone volume and quality have been confirmed, highlighting its potential as a valuable therapeutic tool. Furthermore, the post-operative period following A-PRF treatment has been found to be free of significant discomfort and morbidity for patients, suggesting that this approach may represent a safe and effective means of promoting optimal clinical outcomes.

Introduction

Teeth extraction is the most performed oral surgical intervention in daily dental practice. Indications for extraction are with different etiology, such as extensive and irreparable caries, trauma, periodontitis, cystic and tumorous formations, acute and chronic processes, and extractions due to further orthodontic and prosthetic rehabilitation [1].

The healing of the post-extraction wound is in four phases, which ends with bone modeling and remodeling phase, i.e., bone apposition and resorption [2]. This process is most pronounced in the first 6 months after the extraction of the teeth, during which the bone resorption of the residual alveolar ridge reaches up to two-thirds in the first 3 months [3], [4].

The development of implantology, implant prosthetics, and esthetic dentistry imposes the need for preservation or creation of a biological foundation for so-called red and white esthetics. The preservation of the post-extraction alveola, as a segment of preservation of the residual alveolar ridge, is recommended as the most predictable, economical, and simple preventive method for preserving the original contours of the bone foundation in a horizontal and vertical direction [5], [6]. For this purpose, several types of materials, grafts, and substitutes (autografts, allografts, xenografts, and alloplastic materials) are used which are characterized by their osteogenic, osteoinductive, and/or osteoconductive characteristics [7]. Because of their properties, autografts are rated as the golden standard in these procedures [8].

In 2001, Dr. Choukroun innovated the method of obtaining platelet-enriched fibrin (PRF) as an improved and simplified method in relation to the first generation of platelet-enriched plasma [9]. The PRF protocol is a physiological method based on the use of centrifugal force to fractionate the blood elements of platelet-enriched fibrin in specially designed tubes, lined with glass on the inside, unlike the complicated procedure of obtaining platelet-rich-plasma (PRP) [10]. Platelet-enriched fibrin (PRF) and advanced platelet-rich fibrin (A-PRF) are two different types of platelet-rich fibrin preparations used in medical and dental procedures. Although they have similarities, there are also some differences between them. Here are the key differences:

PRF is prepared by collecting a blood sample from the patient and processing it using a centrifuge

without any anticoagulants or additives. The centrifugation process separates the blood components into three layers: Red blood cells at the bottom, PRF clot in the middle, and platelet-poor plasma at the top. PRF consists of a fibrin clot containing platelets, leukocytes (white blood cells), and growth factors that are naturally present in the blood. It does not contain any additives or anticoagulants [10].

A-PRF is prepared using an advanced centrifugation technique that involves adding an anticoagulant to the blood sample before centrifugation. This anticoagulant prevents blood clotting and allows for the separation of plasma without the formation of a fibrin clot. A-PRF results in a gel-like matrix rather than a solid clot. A-PRF primarily consists of a fibrin matrix rich in platelets and leukocytes. However, due to the use of an anticoagulant during preparation, A-PRF has a higher concentration of platelets compared to PRF. In addition, A-PRF may contain fewer leukocytes compared to PRF [9].

The mechanism of action of PRF is through its structure and composition. It is a network of densely arranged fibrin fibers with three and a tetramolecular structure in which a huge number of platelets and leukocytes are incorporated. By degranulating platelets from their dense α-granules, plasma proteins, pro and anti-inflammatory cytokines (interleukin [IL]-1, IL-6, IL-4, IL-8), and growth factors (transforming growth factor, vascular endothelial growth factor, platelet-derived growth factor, and insulin-like growth factor) are released [11]. The properties of these components that make up the PRF coagulum are in inflammatory response and improvement, as well as the acceleration of bone and soft healing of the post-extraction wound, as well as the elimination of post-operative morbidity.

Due to such properties of PRF, it finds application in several indications in oral and maxillofacial surgery, such as prophylaxis, adjuvant therapy, and treatment: Sinus lift procedures, augmentation of residual alveolar ridge (GBR and ARA), preservation of post-extraction alveola (socket preservation [SP]), periodontal surgery, implantology, treatment of jaw cysts, cheilognathopalatoschisis, bisphosphonate-related osteonecrosis of jaws (BRONJs), osteoradionecrosis, oroantral communications, oral ulcers, and jaw joint disorders (TMD) [12]. The purpose of this study is to compare clinically and radiologically two novel methods of preservation of post-extraction alveola, solo PRF vs. sticky bone, both in terms of quantitative assessment (by evaluating bone resorption in vestibulo-oral and coronaro-apicale aspect) and in terms of quality evaluation of the newly created bone (cone-beam computed tomography [CBCT] evaluation).

Case Reports

Two methods of preservation of post-extraction alveola are evaluated in two patients that have signed informed consent form in accordance with the Helsinki Declaration of 1975, revised in 2013 for the implementation of interventions.

Case 1

This is a case of 29-year-old patient in good general health (ASA I), experiencing consecutive episodes of pericoronitis, pain, inflammation, and abscess in the perimandibular region of the lower right third molar. The following inquiries have been noted:

- The patient's health was clinically evaluated by obtaining a detailed history of the onset and progression of their primary disease, as well as a thorough assessment of their general health status, including any relevant pre-existing medical conditions that may affect their suitability for surgical treatment.
- Clinical examination during which a detailed inspection of the extra and intraoral region was performed, notifying discreet perimandibular swelling on the left side in the corner of the mandible. The area exhibited erythema and a slightly elevated local body temperature. Intraorally, signs of inflammation in the left lower third molar were observed, with purulent content suppuration in the pericoronary area. In addition, first-degree gradation trismus was present.
- Paraclinical examinations, which revealed a number of significant findings. The roentgenological evaluation showed an impacted tooth in a horizontal position, according to the Winter's classification. In addition, a massive carious lesion was observed on the distal surface of the crown of the second molar. The examination also revealed resorption of the interdental septum in an apical aspect, which is presumably a result of poor oral hygiene and a lack of proper physiological self-cleaning. These findings are clearly visible in Figure 1a.

All the above-described findings represented an indication for an operative extraction of the third molar, with a recommendation for preservation of post-extraction alveoli, with "sticky bone", to maintain the periodontal health of the second molar and subsequent conservative treatment of the second molar. After being informed about the proposed therapeutic method, the patient provided written consent for the planed procedure.

Initial conservative treatment of pericoronitis involves rinsing with antiseptic solutions and drainage. After calming the acute symptomatology, an operative intervention was scheduled. Antibiotic prophylaxis with amoxicillin plus clavulanic acid a 2 g, 30 min before the intervention, was given, with intraoral rinsing with cetylpyridinium chloride 0.05% over 2 min.

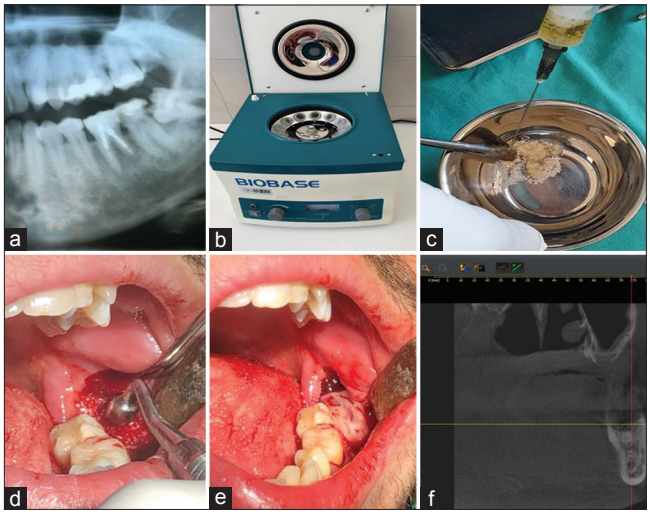

Figure 1: (a) Panoramic view; (b) centrifuge Biobase; (c) sticky bone preparation; (d) sticky bone application; (c) application of platelet-rich fibrin membrane; (f) cone-beam computed tomography post-operative

Shortly before the surgical intervention, the collection of venous blood from a cubic vein by the vacutainer method was done, in two specially designed A-PRF tubes of 10 ml each, placed in the Biobase LC-H4K centrifuge, BIOBASE, Jinan, Guangdong, China, one opposite another, at 1200 spins/min for 8 min (Figure 1b).

Surgical intervention was performed by creating a triangular mucoperiosteal flap, osteotomy near the anatomical neck of the crown of the impacted tooth, separation of the crown and radixes, and minimally invasive extraction of the tooth, with maximum respect for the integrity of the surrounding tissues and soft tissues. Then, a surgical wound debridement was performed and the wound was rinsed with an antiseptic solution of cetylpyridinium chloride 0.05% and physiologic solution.

From the obtained PRF coagulums, two membranes were formed in the special PRF box. Formation of the sticky bone was performed by saturating the xenograft with the supernatant from the tubes, as well as with the chopped pieces from the PRF membrane (Figure 1c). With the help of the PRF sticky bone toolbox, the sticky bone was applied and adapted to the post-extraction alveola by applying mild pressure for discreet condensation and modeling (Figure 1d). The complex graft was covered with a second PRF membrane and sutures were placed (Figure 1e).

Case 2

This is a case of 34-year-old patient experiencing pain and acute periodontal symptomatology in the lower-right first molar region was admitted at the Clinic for Oral Surgery, University Dental Clinical Center “St. Pantelejmon”. Following examinations were done:

- A detailed history of the onset was taken, as well as the patient’s general medical history (which revealed no prior health issues). In addition, information was gathered regarding successive episodes of remission and exacerbation of tooth 46.

The extraoral clinical examination did not reveal signs of infection, while intraoral a periodontal abscess was present, along with signs of inflammation, erythema, and pain on palpation. A vertical resorption (4 mm) of the vestibular cortical lamina in apical direction was observed with a periodontal probe.

- Paraclinical examinations using X-ray evaluations revealed bone rarefication and resorption of interdental septum (Figure 2a).

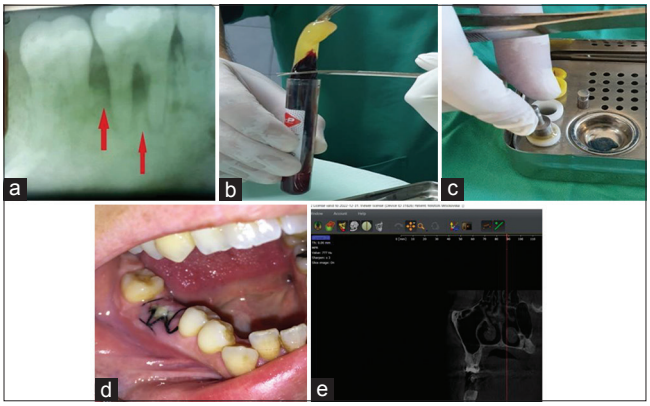

Figure 2: (a) Retroalveolar RTG; (b) preparing platelet-rich fibrin (PRF) coagulum; (c) PRF plug; (d) post-operative solo PRF; (e) post-operative cone-beam computed tomography - solo PRF

Initial conservative perio treatment was conducted, after which signs of local inflammation were calmed.

Due to the existing clinical status, and to preserve the periodontal health of the teeth agonists, and further implant - prosthetic, or prosthetic rehabilitation, surgical therapy implying, extraction of the lower right first molar and subsequent preservation of post-extraction alveoli with solo PRF was recommended.

The intervention was performed according to the protocols of asepsis and antisepsis. Before the intervention, antibiotic prophylaxis with amoxicillin plus clavulanic acid 2g 30 min before intervention and rinsing intraorally with cetylpyridinium chloride 0.05%, over 2 min was administered. The venepuncture was performed using the vacutainer procedure to obtain blood samples, which were collected in two specially designed 10 ml glass-coated A-PRF tubes. The tubes were placed in the centrifuge BIOBASE LC-H4K, BIOBASE, Jinan, Guangdong, China, and centrifuged at 1200 spins/min for 8 min.

Surgical intervention was performed atraumatically, without creating a mucoperiosteal flap (flapless). After extraction, a surgical debridement and a profuse irrigation with an antiseptic solution of cetylpyridinium chloride 0.05% and physiological solution were performed.

From the obtained PRF coagulums (Figure 2b) in PRF box, the PRF plug was formed in the Teflon cups

(Figure 2c). The PRF plug was divided into two parts that were placed in the two post-extraction alveoli of the two radixes of the extracted tooth, with the help of mild pressure with PRF toolbox, and the area was covered with the obtained PRF membrane. The PRF membrane was stabilized by X-suture (Figure 2d).

Results

Immediately after the intervention, the clinical width of the residual alveolar ridge was evaluated. The measurement was performed with a bone measurement caliper in a vestibulo-oral direction. To evaluate the height of the residential alveolar ridge, a graduated periodontal probe was used to measure the distance from the cement-enamel limit of the adjacent tooth to two points: One on the bucco-distal side and the other on the oral distal side, up to the top of the interdental septum. The mean distance between these two points was calculated. In addition, the height of the interdental papilla was measured and noted with a periodontal probe, from the cemento-enamel limit of the adjacent tooth to the highest point of the interdental papilla. The height of the residential alveolar ridge was evaluated, with the help of a graduated periodontal probe, by measuring the distance from the cement-enamel limit of the adjacent tooth to two points, one on bucco-distal side and the other one on the oral distal side, to the top of the interdental septum and taking the mean. The height of the interdental papilla with a periodontal probe was noted, from the cemento-enamel limit of the adjacent tooth to the highest point of the interdental papilla. The same clinical parameters were measured 4 months post-operatively (Table 1).

Table 1: Clinical parameters - Case 1

Parameter	Immediate post-operative (mm)	4-month post-operative (mm)
Horizontal dimension	12.5	11
Vertical dimension	8	5
Papilla height	3	2

Post-operative morbidity was also evaluated, notifying the degree of pain using the visual analogue scale (VAS), presence/absence of post-operative edema, hematoma, infection, regional lymphadenitis, trismus, and the need for painkiller administration.

Four months post-operatively, the quality of the newly formed bone was evaluated with the help of CBCT, 3D imagination technique OWANDY I-MAX 2/3D, and software support Quickvision 2/3D (Owandy Radiology, Croissy-Beaubourg, France) by notifying density, bone density expressed in Hounsfield units (Picture 6 and Picture 11). Collected data are noted in Table 2.

Table 2: Evaluation of the density of the newly formed bone - Case 1

Parameter	CBCT 4-month post-operative (HU)
Post-extraction alveola	776
Periapical region	692

CBCT: Cone beam computed tomography, HU: Household unit.

In the first patient, we performed the procedure using PRF in combination with a xenograft; the following results were obtained:

Evaluation of post-operative morbidity

Immediately after surgical intervention, the patient did not exhibit an elevated body temperature. The patient reported experiencing very minimal pain, rated at a two out of ten on the VAS scale. In addition, there was no post-operative edema, hematoma, trismus, regional lymphadenitis, or functio laesa observed. Only one non-steroidal anti-inflammatory drug was administrated, on the day after the surgical intervention, as an analgesic.

Table 3: Clinical parameters - Case 2

Parameter	Immediate post-operative (mm)	4-month post-operative (mm)
Horizontal dimension	11	9
Vertical dimension	3	3
Papilla height	0	0.5

In the second case, we used solo PRF as a graft material; the following clinical and CBCT results were obtained (Tables 3 and 4).

Table 4: Evaluation of the density of the newly formed bone - Case 2

Parameter	CBCT 4-month post-operative (HU)
Post-extraction alveola	647
Periapical region	777

CBCT: Cone beam computed tomography, HU: Household unit.

Evaluation of post-operative morbidity

Immediately after the surgical intervention, no increased body temperature was observed as well as an absence of a painful sensation with a score of zero according to the VAS scale. In addition, there was an absence of post-operative edema, hematoma, trismus, regional lymphadenitis, or functio laesa. No non-steroidal anti-inflammatory drug was used as analgesics after the surgical intervention.

Discussion

Platelet-enriched fibrin, through its histomorphological characteristics, i.e., its three- and tetramolecular structure, in which 97% of platelets and more than 50% of leukocytes are captured and concentrated, plays a major role in the process of healing of the post-extraction wound, both in hard and soft tissues [13].

Growth factors released by platelet degranulation, from their dense α-granules, play a key role in neocollagenesis and neosteogenesis through their impact on fibroblast and osteoblast activity [14].

The presence of plasma proteins, growth factors, and cytokines in PRF plays a key role in

the processes of hemostasis, angiogenesis, and epithelialization, thereby significantly affecting the healing processes of the post-extraction wound, thus finding application in oral and maxillofacial surgery [15].

Dohan *et al.* in their study describe PRF acting like a lymph node which is able to stimulate defense mechanisms. It is even likely that the significant inflammatory regulation noted on surgical sites treated with PRF is the outcome of retro control effects from cytokines trapped in the fibrin network and released during the remodeling of this initial matrix. Cytokines play a significant role in the delicate balance of tissue homeostasis. IL-1b and IL-1 are produced by the activated macrophages, neutrophils, endothelial cells, fibroblasts, keratinocytes, and Langerhans cells. It is a key mediator of inflammation control. IL-6 principal sources *in vivo* are stimulated monocytes, fibroblasts, and endothelial cells, also a differentiation factor for B lymphocytes and an activator for T lymphocytes. TNF-α is one of the cytokines first released during the inflammatory response to bacterial endotoxin aggression, activates monocytes, and stimulates the remodeling capacities of fibroblasts. In addition, it increases phagocytosis and neutrophil cytotoxicity and modulates the expression of key mediators such as IL-1 and IL-6. IL-4 and IL-4 are produced mainly by a subpopulation of activated T cells (TH2 and CD41) which also secrete IL-6. During inflammatory phenomena, its principal function appears to support healing by moderating inflammation. For example, it increases fibrillary collagen synthesis by fibroblast and inhibits stimulation of MMP-1 and MMP-3 by IL-1b [16].

To improve properties and efficiency, as well as to slow down the release of growth factors and cytokines from the PRF coagulum, several modifications to the protocol for its formation have been made, to the standard A-PRF protocol [17].

In the first clinical case of post-extraction alveolar preservation, the use of A-PRF, as an adjuvant and accelerator, has resulted in noticeable improvement in the properties of the particulate graft material. Specifically, there has been an enhancement of the graft consistency, and the way graft material was manipulated and applied, facilitating the application and thereby reducing the possibility of graft material dissemination at the application site. The obtained clinical measurements indicate an improvement in the effectiveness of the particulate graft in combination with PRF, particularly in terms of preserving the volume of post-extraction alveoli and smaller bone resorption in a horizontal and vertical direction. These results correspond with the results obtained by Yewale *et al.* [18]. On the control CBCT, increased neosteogenesis is notable, as well as better quality and architecture of de novo-formed bone in post-extraction alveola. Similar results have been obtained in several other studies [19].

In the second clinical case where PRF was used as a solo graft material, the clinical measurements showed reduced bone and soft-tissue resorption and reduced loss of the post-extraction alveola volume. This corresponds to the results of several studies, where PRF was used in the preservation of alveola [20], [21]. The evaluation of CBCT, by notifying the density of the newly formed bone in the second clinical case, indicates improved bone formation and uniformed bone architecturalism, which was also noted in other studies [22], [23].

After monitoring post-operative morbidity in both cases, the absence of post-operative sequels can be observed, as well as an elimination of the post-operative discomfort. These results correlate positively with the results obtained in other scientific studies [24], [25].

Conclusion

It can be concluded that A-PRF, as an economical, autologous, and simple graft material, is recommended for use in the preservation of post-extraction alveola, as a solo graft material, or in combination with a particular graft material.

The properties of A-PRF for preserving both bone volume and quality have been confirmed, highlighting its potential as a valuable therapeutic tool. Furthermore, the post-operative period following A-PRF treatment has been found to be free of significant discomfort and morbidity for patients, suggesting that this approach may represent a safe and effective means of promoting optimal clinical outcomes.

References

1. Buchwald S, Kocher T, Biffar R, Harb A, Holtfreter B, Meisel P. Tooth loss and periodontitis by socio-economic status and inflammation in a longitudinal population-based study. J Clin Periodontol. 2013;40(3):203-11. https://doi.org/10.1111/jcpe.12056
PMid:23379538
2. Araújo MG, Silva CO, Misawa M, Sukekava F. Alveolar socket healing: What can we learn? Periodontol 2000. 2015;68(1):122-34. https://doi.org/10.1111/prd.12082
PMid:25867983
3. Araújo MG, Lindhe J. Dimensional ridge alterations following tooth extraction. An experimental study in the dog. J Clin Periodontol. 2005;32(2):212-8. https://doi.org/10.1111/j.1600-051X.2005.00642.x
PMid:15691354
4. Schropp L, Wenzel A, Kostopoulos L, Karring T. Bone healing and soft tissue contour changes following single-tooth extraction: A clinical and radiographic 12-month prospective study. Int J Periodontics Restorative Dent. 2003;23(4):313-23.
PMid:12956475

5. McAllister BS, Haghighat K. Bone augmentation techniques. J Periodontol. 2007;78(3):377-96. https://doi.org/10.1902/jop.2007.060048
   PMid:17335361
6. Hämmerle CH, Araújo MG, Simion M, Osteology Consensus Group 2011. Evidence-based knowledge on the biology and treatment of extraction sockets. Clin Oral Implants Res. 2012;23 Suppl 5:80-2. https://doi.org/10.1111/j.1600-0501.2011.02370.x. Erratum in: Clin Oral Implants Res. 2012;23(5):641.
   PMid:22211307
7. Jamjoom A, Cohen RE. Grafts for ridge preservation. J Funct Biomater. 2015;6(3):833-48. https://doi.org/10.3390/jfb6030833
   PMid:26262646
8. Miron RJ, Hedbom N, Saulacic Y, Zhang Y, Sculean A, Bosshardt DD, *et al*. Osteogenic potential of autogenous bone grafts harvested with four different surgical techniques. J Dent Res. 2011;90(12):1428-33. https://doi.org/10.1177/0022034511422718
   PMid:21940523
9. Choukroun J, Adda F, Schoeffler C, Vervelle A. An opportunity in implantology: The PRF. Implantodontie. 2001;42:55-62.
10. Marx RE. Platelet-rich plasma: Evidence to support its use. J Oral Maxillofac Surg. 2004;62(4):489-96. https://doi.org/10.1016/j.joms.2003.12.003
    PMid:15085519
11. Dohan DM, Choukroun J, Diss A, Dohan SL, Dohan AJ, Mouhyi J, *et al*. Platelet-rich fibrin (PRF): A second-generation platelet concentrate. Part II: platelet-related biologic features. Oral Surg Oral Med Oral Pathol Oral Radiol Endod. 2006;101(3):e45-50. https://doi.org/10.1016/j.tripleo.2005.07.009
    PMid:16504850
12. Al-Hamed FS, Mahri M, Al-Waeli H, Torres J, Badran Z, Tamimi F. Regenerative effect of platelet concentrates in oral and craniofacial regeneration. Front Cardiovasc Med. 2019;6:126. https://doi.org/10.3389/fcvm.2019.00126
    PMid:31552270
13. Ehrenfest DM, Del Corso M, Diss A, Mouhyi J, Charrier JB. Three-dimensional architecture and cell composition of a Choukroun's platelet-rich fibrin clot and membrane. J Periodontol. 2010;81(4):546-55. https://doi.org/10.1902/jop.2009.090531
    PMid:20373539
14. Kawase T, Okuda K, Wolff LF, Yoshie H. Platelet-rich plasma-derived fibrin clot formation stimulates collagen synthesis in periodontal ligament and osteoblastic cells *in vitro*. J Periodontol. 2003;74(6):858-64. https://doi.org/10.1902/jop.2003.74.6.858
    PMid:12886997
15. Del Corso M, Vervelle A, Simonpieri A, Jimbo R, Inchingolo F, Sammartino G, *et al*. Current knowledge and perspectives for the use of platelet-rich plasma (PRP) and platelet-rich fibrin (PRF) in oral and maxillofacial surgery part 1: Periodontal and dentoalveolar surgery. Curr Pharm Biotechnol. 2012;13(7):1207-30. https://doi.org/10.2174/138920112800624391
    PMid:21740371
16. Dohan DM, Choukroun J, Diss A, Dohan SL, Dohan AJ, Mouhyi J, *et al*. Platelet-rich fibrin (PRF): A second-generation platelet concentrate. Part III: Leucocyte activation: A new feature for platelet concentrates? Oral Surg Oral Med Oral Pathol Oral Radiol Endod. 2006;101(3):e51-5. https://doi.org/10.1016/j.tripleo.2005.07.010
    PMid:16504851
17. Kobayashi E, Flückiger L, Fujioka-Kobayashi M, Sawada K, Sculean A, Schaller B, *et al*. Comparative release of growth factors from PRP, PRF, and advanced-PRF. Clin Oral Investig. 2016;20(9):2353-60. https://doi.org/10.1007/s00784-016-1719-1
    PMid:26809431
18. Yewale M, Bhat S, Kamath A, Tamrakar A, Patil V, Algal AS. Advanced platelet-rich fibrin plus and osseous bone graft for socket preservation and ridge augmentation-a randomized control clinical trial. J Oral Biol Craniofac Res. 2021;11(2):225-33. https://doi.org/10.1016/j.jobcr.2021.01.016
    PMid:33665072
19. Nevins ML, Camelo M, Schupbach P, Kim DM, Camelo JM, Nevins M. Human histologic evaluation of mineralized collagen bone substitute and recombinant platelet-derived growth factor-BB to create bone for implant placement in extraction socket defects at 4 and 6 months: A case series. Int J Periodontics Restorative Dent. 2009;29(2):129-39.
    PMid:19408475
20. Anwandter A, Bohmann S, Nally M, Castro AB, Quirynen M, Pinto N. Dimensional changes of the post extraction alveolar ridge, preserved with leukocyte-and platelet rich fibrin: A clinical pilot study. J Dent. 2016;52:23-9. https://doi.org10.1016/j.jdent.2016.06.005
    PMid:27338946
21. Temmerman A, Vandessel J, Castro A, Jacobs R, Teughels W, Pinto N, *et al*. The use of leucocyte and platelet-rich fibrin in socket management and ridge preservation: A split-mouth, randomized, controlled clinical trial. J Clin Periodontol. 2016;43(11):990-9. https://doi.org/10.1111/jcpe.12612
    PMid:27509214
22. Tatullo M, Marrelli M, Cassetta M, Pacifici A, Stefanelli LV, Scacco S, *et al*. Platelet rich fibrin (P.R.F.) in reconstructive surgery of atrophied maxillary bones: Clinical and histological evaluations. Int J Med Sci. 2012;9(10):872-80. https://doi.org/10.7150/ijms.5119
    PMid:23155361
23. Areewong K, Chantaramungkorn M, Khongkhunthian P. Platelet-rich fibrin to preserve alveolar bone sockets following tooth extraction: A randomized controlled trial. Clin Implant Dent Relat Res. 2019;21(6):1156-63. https://doi.org/10.1111/cid.12846
    PMid:31647177
24. Uyanik LO, Bilginaylar K, Etikan İ. Effects of platelet-rich fibrin and piezosurgery on impacted mandibular third molar surgery outcomes. Head Face Med. 2015;11:25. https://doi.org/10.1186/s13005-015-0081-x
    PMid:26209242
25. Kumar N, Prasad K, Ramanujam K, Dexith J, Ranganath K, Chauhan A. Evaluation of treatment outcome after impacted mandibular third molar surgery with the use of autologous platelet-rich fibrin: A randomized controlled clinical study. J Oral Maxillofac Surg. 2015;73(6):1042-1049. https://doi.org/10.1016/j.joms.2014.11.013
    PMid:25659357